ORIGINAL STUDY

Acute Encephalitis Syndrome – A Presentation of Ascaris Toxin

AVINASH SHANKAR*, SHUBHAM†, AMRESH SHANKAR‡, ANURADHA SHANKAR#

ABSTRACT

Acute encephalitis syndrome (AES) is primarily caused by virus; but other pathogens cannot be ignored as prompt and correct clinical acumen saves many lives. This study represents the evaluation and treatment of 147 cases of AES admitted at our center who were managed based on previous experience of similar AES prevalence in 1985, in nutritionally deprived patients of poor socioeconomic status with history of passing round worms. We saved all 147 cases without any adversity or adjuvant required or mortality and all patients passed round worms on deworming (albendazole and ivermectin) in therapeutic dose for 3 consecutive days, after 7th day of discharge. Majority of the patients regained consciousness within 48 hours of therapy while seizures ceased in all cases by 12 hours of therapy. Thus, consider round worm encephalopathy in nutritionally deprived patients of AES in addition to other pathogens as right approach will save life, time and cost of therapy. Round worms cause encephalopathy due to competitive inhibition of pyridoxal 5 phosphate coenzyme, a prime coenzyme for gamma-aminobutyric acid synthesis and metabolism in brain by its polypeptide secretion in adverse situation.

Keywords: Acute encephalitis syndrome, round worm encephalopathy, pyridoxal 5 phosphate, gamma-aminobutyric acid

Febrile convulsion is not a new presentation but continuing since long and the disease gravity is increasing progressively. Initially, acute encephalitis syndrome (AES) was claimed to be solely due to viral infection and was termed Japanese encephalitis but these days the presentation is being termed as AES. In spite of available therapeutics and advanced diagnostic tools, the mortality remains the same even at higher centers.

*Chairman
Institute of Applied Medicine
National Institute of Health & Research, Warisaliganj (Nawada), Bihar
†Consultant Pediatrician
RA Hospital & Research Centre, Warisaliganj (Nawada), Bihar
‡Hon Director
Aarogyam Punarjeevan, Patna, Bihar
#Ex-Director
Centre for Indigenous Medicine & Research
Senior Research Fellow cum Medical Officer
Regional Institute of Ayurveda Research
Itanagar, Arunachal Pradesh
Address for correspondence
Dr Avinash Shankar
Chairman
Institute of Applied Medicine
National Institute of Health & Research, Warisaliganj (Nawada), Bihar - 805130
E-mail: dravinashshankar@gmail.com

Acute encephalitis is clinically diagnosed in children with acute onset of symptoms and signs of inflammatory lesions in the brain. Changes in sensorium, seizures and upper motor neuron type of altered muscle tone are suggestive of cerebral dysfunction.

The clinical picture involves a prodromal phase of 1-3 days that includes fever, malaise and headache and an encephalitic phase with continued fever, decreasing level of consciousness, seizures, abnormal movements or paralysis. Signs of meningeal inflammation are absent or minimal.

In summary, all that presents with fever and cerebral dysfunction is not acute encephalitis.

Acute encephalitis is usually caused by any of the several neurotrophic viruses. A large number of these are vector-transmitted (arthropod-borne) arboviruses. In India, Japanese encephalitis (JE) virus is the commonest.

Clinical neurologic manifestations are caused by a wide range of viruses, bacteria, fungi, parasites, spirochetes, chemicals and toxins. Correct management will depend on the correct diagnosis.

Considering a similar disease prevalence among the downtrodden and nutritionally deprived children in 1985 that proved to be a manifestation of

Ascaris lumbricoides toxin and majority were saved, similar line of treatment was evaluated in patients with AES in this study who presented at RA Hospital & Research Centre, Warisaliganj (Nawada), Bihar with the prime motive of ensuring cure in the majority.

OBJECTIVE OF THE STUDY

The objective of the study was to ensure cure in majority of the patients and to ascertain the cause of presentation.

MATERIAL AND METHODS

Patients with complaints of AES attending Medical Emergency of RA Hospital & Research Centre from May to July 5, 2019 were considered for the study.

Parents of the admitted patients were thoroughly interrogated for onset of the disease and its progression. Patients were clinically evaluated, investigated and provided basic life support and were administered:

- Oxygen inhalation
- Ryle's tube intubation for feeding (bland, sweet, liquid oral) and antacid with oxetacaine 2.5 mL every 6 hours
- IV mannitol 10% with glycerine 10% in dose of 10 mL/kg every 12 hours
- Injection sodium valproate with pediatric IV solution
- Injection amikacin 7.5 mg/kg every 12 hours
- IV pediatric solution *plus* methylcobalamin, pyridoxine and nicotinamide ½-1 mL slow infusion
- Herbal ointment (constituting of pure ghee, *Mentha piperita*, *Cinnamomum camphora*, oil of *Caryophyllus aromaticus*, oil of *Cinnamomum zeylanicum*) for local chest application
- Herbal composite syrup through feeding tube 1.25-2.5 mL every 12 hours
- Frequent change of posture
- Cold sponging.

Patients were observed for:

- Fever
- Convulsion
- Consciousness status
- Any evident paresis
- Any unusual presentation.

On discharge on 5th day, patients were advised:

- Suspension of aluminum hydroxide, magnesium hydroxide, simethicone, oxetacaine 2.5 mL three times daily
- Herbal composite syrup 1.25-2.5 mL every 12 hours
- Syrup sodium valproate 1.25-2.5 mL every 8 hours
- Syrup B complex 2.5 mL twice-daily
- Bland, simple and sweet oral liquid diet.

After a week, for deworming, patients were advocated:

- Albendazole *plus* ivermectin suspension in dose of 5-10 mL at bed time for 3 consecutive days.

After deworming patients were advised:

- Herbal composite syrup 1.25-2.5 mL every 12 hours for 2 months
- Syrup B complex 2.5-5 mL twice-daily for 2 months
- Deworming every month for 3 days for 3 consecutive months every year
- High protein diet
- Restrict biscuits, Kurkure, etc.

OBSERVATIONS AND RESULTS

Overall, 147 patients were selected for the study in the age group of 2-14 years and majority (38.8%) were in the age group of 5-8 years. Nearly 10.9% were in the age group of 11-14 years (Table 1). Out of the 147 patients, 99 were males and 48 were females (Fig. 1).

Majority (45.6%) of the patients were suffering for 6-12 hours while 7.4% patients were suffering for more than 24 hours (Fig. 2).

Majority (55.8%) patients attended the center after 12-18 hours of onset of disease while 9.5% after >24 hours (Fig. 3).

Out of all, 44.9% were having temperature >102°F, 95.2% each had tonic-clonic convulsions and unconsciousness,

Table 1. Distribution of Patients as per Age and Sex

Age group (in years)	Number of patients			
	Male	Female	Total	Percentage
2-5	31	17	48	32.7
5-8	40	17	57	38.8
8-11	17	09	26	17.6
11-14	11	05	16	10.9

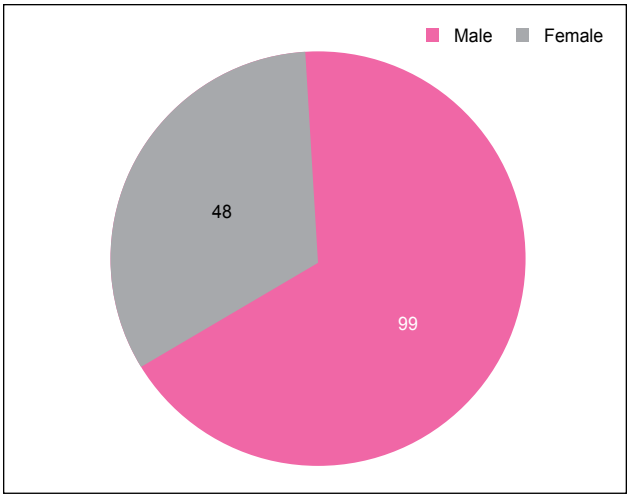

Figure 1. Number of male and female patients.

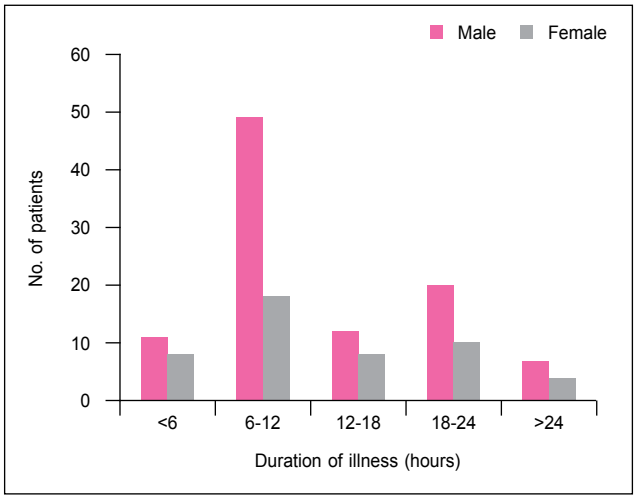

Figure 2. Distribution of patients as per duration of illness.

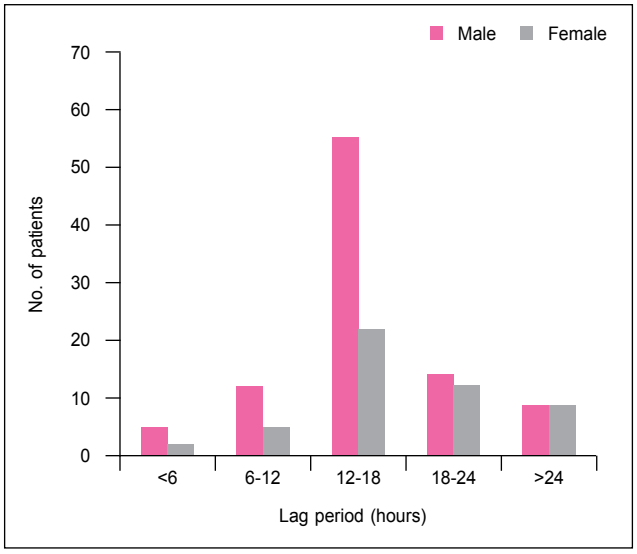

Figure 3. Distribution of patients as per lag period in attending our center.

Table 2. Distribution of Patients as per their Presenting Features

Particulars	Number of patients
Fever	
>102°F	66
<102°F	81
Convulsions	
Tonic-clonic	140
Mild jerks	07
Loss of sensation	147
Consciousness	
Unconscious	140
Conscious	07
Abnormal behavior	07
History of helminthiasis	87
Recurrent loose motion	147
Abdominal distension	147
Urticarial rash	87
Clinical examination	
Pot belly abdomen	104
Signs of malnutrition	147
Palpable liver	90
Investigations	
CBC shows raised eosinophil	147
Hemoglobin:	
<10 gm%	107
>10 gm%	40
CSF	No abnormality seen
X-ray chest	No abnormality detected
X-ray abdomen	Distended intestinal loop
Blood for malarial antigen	None
Widal	Nonreactive
Blood and CSF for viral analysis	No virus detected
EEG	No evident pathology
CT brain	No evident pathology

CBC = Complete blood count; CSF = Cerebrospinal fluid; ECG = Electroencephalogram; CT = Computed tomography.

70.7% had pot belly abdomen. There was history of passing round worm and urticarial rashes in past in 59.2%. About 72.8% showed hemoglobin <10 gram%.

Signs of malnutrition and raised eosinophil count were present in all the cases (Table 2).

Majority of the patients regained consciousness in 12 hours, though 27 cases took 40 hours to regain consciousness. Convulsion seized within 12 hours in all the cases irrespective of their age or lag period.

Feeding tube was removed after 48 hours in all the cases. No patients presented with any residual paresis or neuropsychiatric changes.

After a week, administration of albendazole with ivermectin suspension at bedtime for 3 consecutive days ensured passage of round worms in all the cases. Post-therapy 2-week follow-up revealed no untoward effects or withdrawal manifestation. Repeat basic bioparameters in all cases showed no alteration in any of the cases.

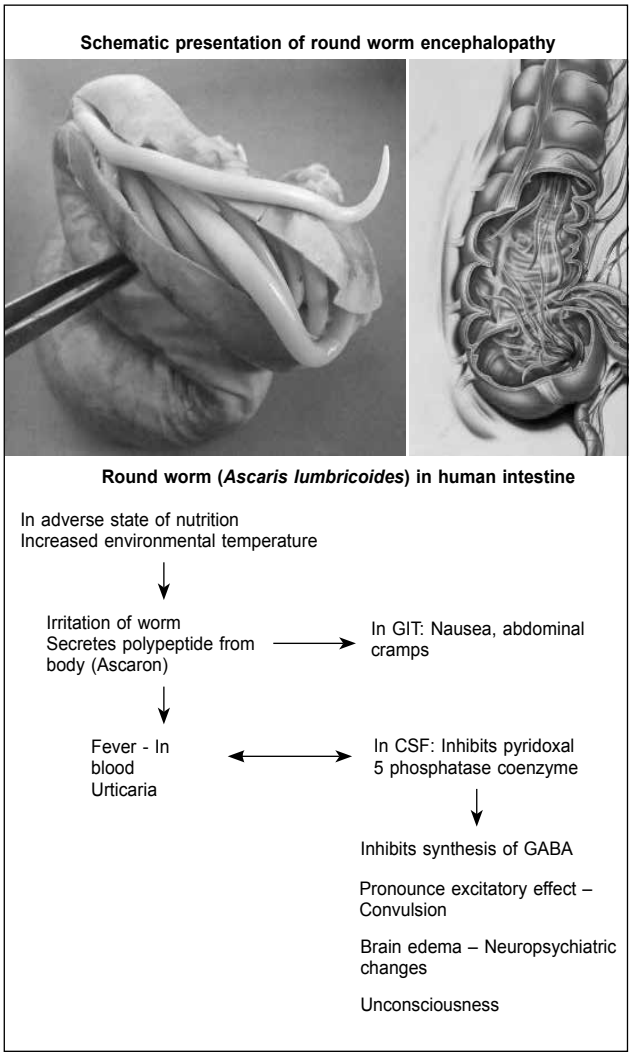

Figure 4. Pathogenesis of round worm encephalopathy.

GIT = Gastrointestinal tract; GABA = Gamma-aminobutyric acid.

DISCUSSION

Nutritionally deprived patients with AES admitted at our center having history of passing round worm in past, vomiting and diarrhea, occasional urticarial rash, fever, were treated conventionally on the line of round worm encephalopathy evident during 1985 and showed complete recovery within 48 hours and passed round worms on deworming on 7th day after discharge.

Figure 4 summarizes the pathogenesis of round worm encephalopathy.

Round worm causes encephalopathy due to competitive inhibition of pyridoxal 5 phosphate coenzyme, a prime

Table 3. Plan of Therapy and its Effect

Oxygen inhalation	To ensure appropriate energy need of brain cells and check hypoxic degeneration.
IV mannitol 10% with glycerine 10%	To reduce brain edema.
IV pyridoxine	To facilitate pyridoxal 5 phosphatase coenzyme responsible for formation of GABA from glutamic acid and its metabolism by activating enzyme glutamate decarboxylase and GABA transaminase.
IV sodium valproate	To control seizure.
Through Ryle's tube antacid with oxetacaine	Antacid solution coats intestinal mucosa, checks toxin absorption, intestinal irritation. Oxetacaine acts as local anesthetic on round worm body, calms the worm, check its irritation and secretion of polypeptide.
Herbal neurogen	Revitalize damaged neural cells, energize the brain cells and preserve neural cell function.
Bland, simple, sweet liquid oral diet	To facilitate nutrition to child.
Antimicrobial therapy	To check super infection.
Herbal chest application	To facilitate reabsorption of lung fluid and check respiratory infection.
Cold sponging	To decrease body temperature and prevent neural cell integrity.

IV = Intravenous

coenzyme for gamma-aminobutyric acid synthesis and metabolism in brain by its polypeptide secretion in adverse situation.

Table 3 summarizes the plan of therapy and its effect.

CONCLUSION

All cases of AES responded well to the regime with 100% survival without any untoward effects or sequelae and proved to be due to *Ascaris lumbricoides* toxin. Thus, in AES in nutritionally deprived patients, round worm encephalopathy must be kept in mind.

SUGGESTED READING

1. Prober CG, Srinivas NS, Mathew R. Central nervous system infections. In: Kliegman RM, Stanton BF, St. Geme JW, Schor NF (Eds.). Nelson Textbook of Pediatrics. 20th Edition, New Delhi: Reed Elsevier India Pvt. Ltd; 2016. pp. 2936-48.
2. Shah AB, John TJ. Recurrent outbreaks of hypoglycaemic encephalopathy in Muzaffarpur, Bihar. Curr Sci. 2014;107(4):570-1.
3. Joshi R, Kalantri SP, Reingold A, Colford JM Jr. Changing landscape of acute encephalitis syndrome in India: a systematic review. Natl Med J India. 2012;25(4):212-20.
4. Jain P, Jain A, Kumar A, Prakash S, Khan DN, Singh KP, et al. Epidemiology and etiology of acute encephalitis syndrome in North India. Jpn J Infect Dis. 2014;67(3):197-203.
5. Kakkar M, Rogawski ET, Abbas SS, Chaturvedi S, Dhole TN, Hossain SS, et al. Acute encephalitis syndrome surveillance, Kushinagar district, Uttar Pradesh, India, 2011-2012. Emerg Infect Dis. 2013;19(9):1361-7.
6. John TJ, Verghese VP, Arunkumar G, Gupta N, Swaminathan S. The syndrome of acute encephalitis in children in India: Need for new thinking. Indian J Med Res. 2017;146(2):158-61.
7. Shankar A. Round worm encephalopathy. Antiseptic. 1987. pp. 595-8.
8. Bayoumi RA, Kirwan JR, Smith WR. Some effects of dietary vitamin B6 deficiency and 4-deoxypyridoxine on γ-aminobutyric acid metabolism in rat brain. J Neurochem. 1972;19(3):569-76.
9. Coursin DB. Vitamin B6 and brain function in animals and man. Ann N Y Acad Sci. 1969;166(1):7-15.
10. Gale K. Mechanisms of seizure control mediated by gamma-aminobutyric acid: role of the substantia nigra. Fed Proc. 1985;44(8):2414-24.
11. Kaufman DL, Houser CR, Tobin AJ. Two forms of the gamma-aminobutyric acid synthetic enzyme glutamate decarboxylase have distinct intraneuronal distributions and cofactor interactions. J Neurochem. 1991;56(2):720-3.
12. Martin DL, Martin SB, Wu SJ, Espina N. Cofactor interactions and the regulation of glutamate decarboxylase activity. Neurochem Res. 1991;16(3):243-9.
13. Martin DL, Rimvall K. Regulation of gamma-aminobutyric acid synthesis in the brain. J Neurochem. 1993;60(2):395-407.
14. Miller LP, Walters JR, Martin DL. Post-mortem changes implicate adenine nucleotides and pyridoxal-5' -phosphate in regulation of brain glutamate decarboxylase. Nature. 1977;266(5605):847-8.
15. Tews JK. Pyridoxine deficiency and brain amino acids. Ann N Y Acad Sci. 1969;166(1):74-82.