CASE REPORT

Paroxysmal Visual Phenomenon: A Rare and Confusing Manifestation of Occipital Neurocysticercosis in Children

DEVENDRA MISHRA*, AJAY GARG†

ABSTRACT

We report a child with occipital inflammatory granuloma of neurocysticercosis who presented with paroxysmal visual phenomenon and discuss its differentiation from migraine aura. Occipital seizures due to neurocysticercosis must be considered in the differential diagnosis of visual hallucinations in children in endemic areas.

Keywords: Occipital seizures, migraine aura, visual hallucinations, inflammatory granuloma

Among Indian children, neurocysticercosis is a common cause of seizures, both partial and generalized.[1] The commonest site of intraparenchymal neurocysticercosis in this region has been reported to be parieto-occipital, with occipital lesions being somewhat uncommon.[2] Paroxysmal visual phenomenon in a child may either represent an aura (a brief subjective symptom representing the initial manifestation of a partial epileptic seizure) or may constitute the entire epileptic seizure arising from the occipital lobe. If recurrent, such attacks may also cause diagnostic confusion with prodrome phase of classic or basilar migraine,[3] or with a specific variety of migraine 'typical aura without headache' (Category 1.2.3, International Headache Society classification).[4] We herein report a pediatric patient with occipital lesion of neurocysticercosis, presenting with elementary sensory (visual) symptomatology.

*Assistant Professor
Dept. of Pediatrics
Chacha Nehru Bal Chikitsalaya, (Maulana Azad Medical College)
Geeta Colony, New Delhi
†Assistant Professor
Dept. of Neuroradiology
All India Institute of Medical Sciences, Ansari Nagar, New Delhi
Address for correspondence:
Dr Devendra Mishra
163, Sahyog Apartments
Mayur Vihar Phase I, Delhi-91

CASE REPORT

A 9-year-old male child with normal development and no suggestive past history presented with complaints of one episode of visual symptoms followed by loss of awareness in the class at school. Semiology of the event (as elicited from the child and confirmed from classmates and teacher) consisted of visual disturbance in the form of uniform abnormal (red) discoloration of objects lasting for 30-45 seconds in the whole field of vision, followed by non-responsiveness for a period of about 2-3 minutes. No clear history regarding onset in one-side of visual field later spreading to the other side, could be elicited. There was no vomiting or weakness following the episode. There was no history of prolonged standing or exercise prior to the episode. There was no history of headache. Systemic and ophthalmic examinations, and the interictal EEG were normal. Magnetic resonance imaging head (Fig. 1) revealed a ring-enhancing lesion in the occipital lobe with imaging features characteristic of neurocysticercosis.[5] Serum electroimmunotransfer blot (EITB) assay, and cerebrospinal fluid (CSF)-Enzyme linked immunosorbent assay (ELISA) and EITB for cysticercosis could not be done. Serum ELISA for cysticercosis was positive, and there were no positive examination or laboratory finding suggestive of tuberculosis at any other site. Patient was managed as a case of single neurocysticercosis granuloma according to the departmental protocol with anticonvulsants (carbamazepine, 12 mg/kg/day, divided TID), cysticidal therapy (albendazole 15 mg/kg/day for 28 days) and

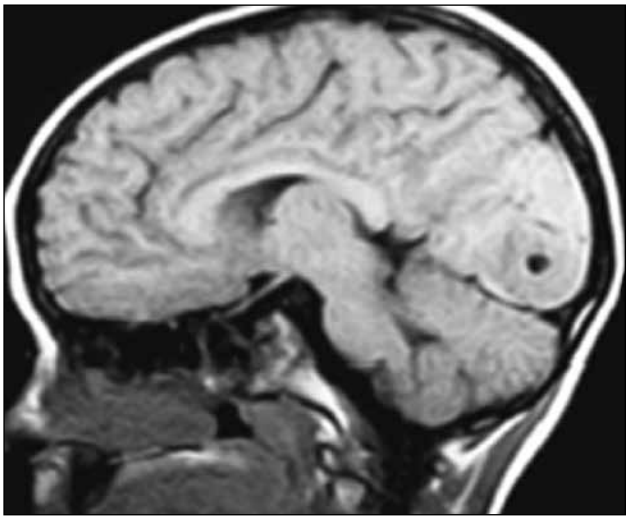

Figure 1. MRI-head showing an inflammatory granuloma located near the lingual gyrus of occipital lobe.

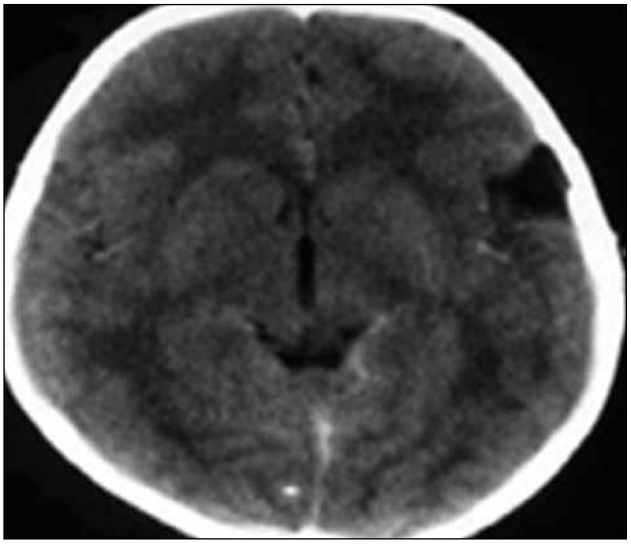

Figure 2. Follow-up CT scan 7½-month later shows calcification of the lesion.

steroids (dexamethasone for 5 days). He had two further similar episodes 17 day and 21 day after start of therapy, for which anticonvulsant dose were increased. The child is at presently receiving carbamazepine 18 mg/kg/day, divided thrice a day and is asymptomatic. A repeat neuroimaging of the head 7½-months later revealed calcification of the lesion (Fig. 2).

DISCUSSION

Migraine and epilepsy are easy to differentiate, however, there are cases, mainly children, with considerable difficulty in their differentiation.[3] Visual manifestations are the most common form of migraine aura.[4] Such phenomenon usually lasts 5-30 minutes and shows a marching phenomenon. Visual phenomenon may also be the presenting symptoms of an occipital seizure. Paroxysmal visual manifestations representing occipital seizures may present in form of blurred vision, loss of focus, seeing colored dots, or brief stereotyped complex visual hallucinations like seeing unfamiliar faces or scenes. Because of the similar features, the visual hallucinations associated with occipital lobe lesions may be confused with the aura of migraine.[6] Visual hallucinations associated with seizures differ from those of migraine in that they are of short duration, lack a fortification spectrum, are typically invariant from one episode to another, lack a march or build-up of the visual disturbance, always occur in the same hemifield (contralateral to the lesion), and may be followed by motor seizures.[3,7,8] They may however show similarities with migraine visual hallucinations in that they may spread across the whole visual field, be followed by a headache or vomiting.

Isolated visual seizures due to neurocysticercosis have previously been reported in adult patients but not in children, probably because it is an infrequent location for neurocysticercosis in children,[1,2] or younger children may not be able to clearly describe the event for the physician to make a diagnosis of visual seizures. Sharma et al reported 4 adult patients with occipital neurocysticercosis and complaints of seeing bright lights on the lateral side of the field of vision. Two of these also had associated mild headache, and one had a visual field defect.[6] In our patient, formal visual field testing could not be done but the child had no visual field related complaints and normal confrontation testing. Most patients with lateral occipital lesions have been reported not to have visual field defects.[7] In this case, however the lesion was located in the lingual gyrus of the occipital lobe (Fig.1). Garg et al reported occipital lesions in one-fifth of 4-18 year old seizure patients with single enhancing CT lesions and 16 (80%) of these had visual aura.[8] However, these were followed by generalized seizures and tonic deviation of eyes and/or head in 9 and 7 patients, respectively. Isolated visual phenomenon was not seen in any of these patients.[8] The EEG was normal in our patient, which is similar to the findings in previously reported cases.[6,7] As different from previous reports, visual hallucinations in this child were colored and spread across the whole of the field, which is much more suggestive of a migraine aura.[3] Although the possibility remains that transient motor manifestations in this child could have been missed by the eyewitnesses during the first-

episode, the subsequent two episodes that occurred in home were observed by the parents and had no motor component.

To conclude, we describe a child with migraine-like visual phenomenon as the only manifestation of occipital neurocysticercosis. In view of the current case and similar reports in adults,[6] we suggest that in endemic regions like India, occipital seizures due to neurocysticercosis should be considered as a diagnostic possibility in patients presenting with visual hallucinations, even when there are no associated motor manifestations.

REFERENCES

1. Kalra V, Mittal R, Rana KS, Gupta A. Neurocysticercosis: Indian experience. New Developments in Neurology. Bologna, Italy; Monduzzi Editore SpA 1998;353-59.
2. Hussain J, Srinivasan S, Serane VT, Mahadevan S, Elangovan S, Bhuvaneswari V. Cranial computed tomography in partial motor seizures. Indian J Pediatr. 2004;71(1): 641-4.
3. Panayiotopoulos CP. Elementary visual hallucinations in migraine and epilepsy. J Neurol Neurosurg Psychiatry. 1994;57(11):1371-74.
4. Headache Classification Subcommittee of the International Headache Society. The International Classification of Headache Disorders, 2nd edition. Cephalalgia. 2004;24 Suppl 1:9-160.
5. Rajshekhar V, Haran RP, Prakash GS, Chandy MJ. Differentiating solitary small cysticercus granulomas and tuberculomas in patients with epilepsy. Clinical and computerized tomographic criteria. J Neurosurg. 1993;78(3): 403-7.
6. Sharma K, Wahi J, Phadke RV, Varma A, Jain VK. Migraine-like visual hallucinations in occipital lesions of cysticercosis. J Neuroophthalmol. 2002;22(2):82-7.
7. Williamson PD, Thadani VM, Darcey TM, Spencer DD, Spencer SS, Mattson RH. Occipital lobe epilepsy: clinical characteristics, seizure spread patterns, and results of surgery. Ann Neurol. 1992;31(1):3-13.
8. Garg RK, Nag D. Single enhancing CT lesions in Indian patients with seizures: clinical and radiological evaluation and follow-up. J Trop Pediatr. 1998;44(4):204-10.

...Cont'd from page 18

2. Lawrence R. Pediatric septoplasy: a review of the literature. Int J Pediatr Otorhinolaryngol. 2012;76(8):1078 -81.
3. Cervera Escario J, Castillo Martín FD, Gómez Campderá JA, Gras Albert JR, Pérez Piñero B, Villafruela Sanz MA. Indications for tonsillectomy and adenoidectomy: consensus document by the Spanish Society of ORL and the Spanish Society of Pediatrics. Acta Otorrinolaringol Esp. 2006;57(2): 59-65.
4. Adams DA, Cinnamon MJ. Pediatric otolaryngology volume 6, Scott-Brown's Otorhinolaryngology: Head and Neck Surgery; 6th edition, Butterworth-Heinemann. 1997 nasal obstruction and rhinorrhea in infants and children, 6w/17/1-14.