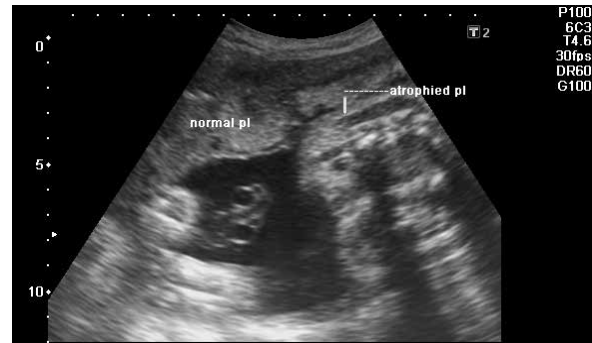


## PICTURE QUIZ

# What is the Diagnosis?

This is an ultrasound report of a 20-year-old primigravida at 32 weeks of gestation, what is the presumptive diagnosis?

- a) Monochorionic monoamniotic twins
- b) Single intrauterine fetal demise
- c) Normal twin pregnancy
- d) Vanishing twin syndrome



Answer to the Picture Quiz from the Indian Journal of Clinical Practice, Vol. 35, No. 10, March 2025

**Answer: (a)** Molar pregnancy caused by “high dose hook effect”

See Answer in the Next Month's Issue!