

CASE REPORT

Herpes Zoster Ophthalmicus in Healthy 13-month Infant: An Unforeseen Scenario

DHAVALKUMAR S BANSODE*, SONIA P JAIN†, ABHAY DESHMUKH‡, PRATIKSHA MORESHWAR SONKUSALE#

ABSTRACT

Herpes zoster (HZ) as well as varicella are caused by varicella-zoster virus. It is uncommon in children. Cases have been reported in literature among all ages from neonate to old age. We report this case of HZ ophthalmicus in a healthy child born to healthy mother with a history of varicella infection in the third trimester (7th month of gestation). Early diagnosis and treatment reduce complications. Preconceptional varicella-zoster vaccine is also a matter of concern.

Keywords: Herpes zoster ophthalmicus, infant, varicella-zoster vaccine, varicella-zoster

Herpes zoster (HZ) and varicella are caused by the same virus, i.e., varicella-zoster virus¹. Cases have been reported in medical literature from neonates to old age, but it is rare in immunocompetent children. Overall incidence of HZ is 3.4/1,000 people, whereas in children in the age group of 0 to 9 years and 10 to 19 years it is 0.74 and 1.38, respectively². Herpes zoster ophthalmicus (HZO) is caused by varicella-zoster virus 3, i.e., human herpes virus 3.

Presented here is the case of a 13-month-old baby with HZO.

CASE REPORT

A 13-month-old, 7.5 kg, female child, born full-term, normal vaginal delivery, was brought with vesicular eruptions over right side of forehead, erythema and swelling over right upper eyelid since 4 days. It was accompanied with photophobia and watery discharge from the right eye. Cutaneous examination revealed multiple, tense, grouped vesicular lesions with erosions and yellow crust on erythematous base present over scalp, forehead extending to right periorbital region,

nasal bridge and tip of nose (Fig. 1), suggesting involvement of nasociliary branch of the ophthalmic division of right trigeminal nerve, thus positive Hutchinson's sign. There was marked erythema and swelling of the right upper eyelid with difficulty in opening of right eye.

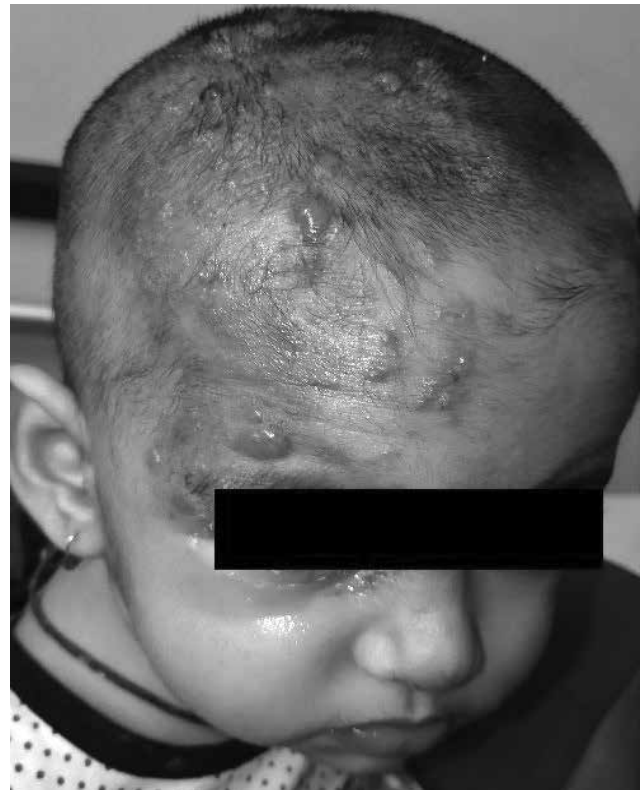

Figure 1. Vesicular eruption over right side of forehead, nose and tip of nose with marked erythema and swelling of right upper eyelid.

*Junior Resident

†Professor

Dept. of DVL

‡Assistant Professor, Dept. of Pathology

#Assistant Professor, Dept. of DVL

MGIMS, Sevagram, Wardha, Maharashtra, India

Address for correspondence

Dr Sonia P Jain

A-14, Dhanvantri Nagar, MGIMS, Sevagram, Wardha - 442 102, Maharashtra, India

E-mail: soniadjain@rediffmail.com

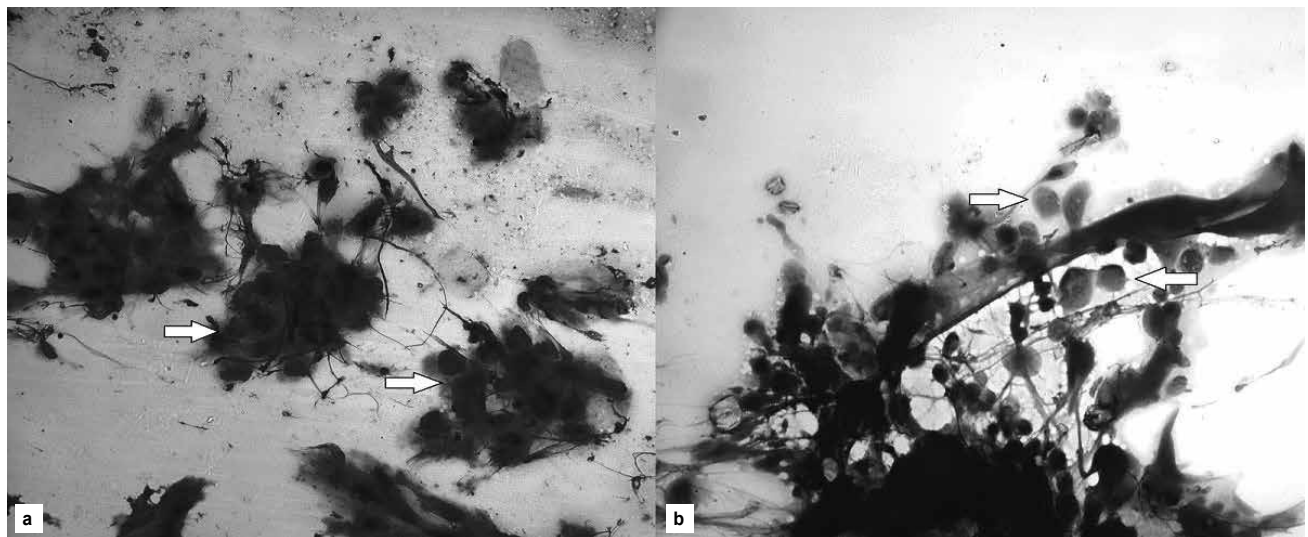


Figure 2. Smear showing presence of multinucleated giant cells (*white arrow*) (Giemsa, x400) (a) and acantholytic cells (*white arrow*) (PAP, x400) (b).

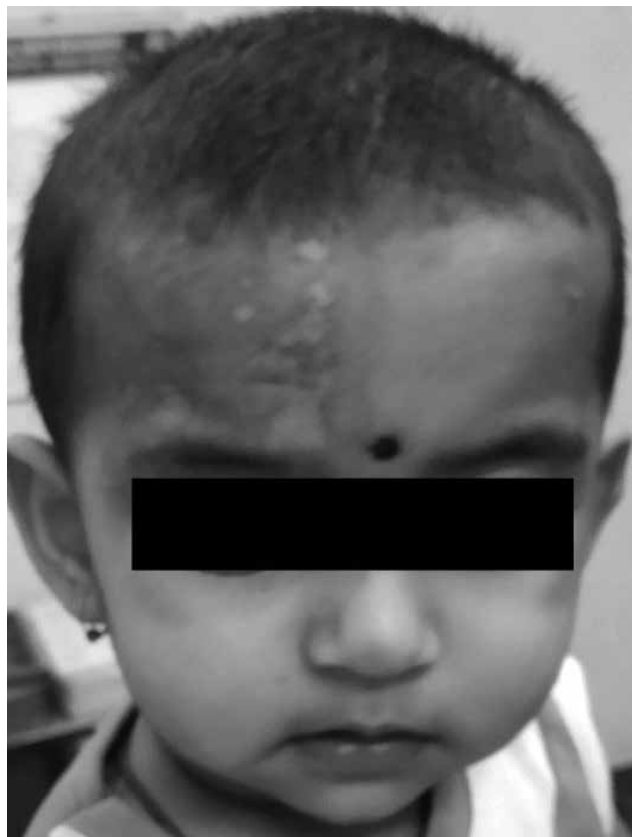

Figure 3. Complete resolution after 1 week of treatment.

On ophthalmic consultation, tobramycin eye drop twice and lubricating eye drop four times a day were started. Visual acuity was difficult to assess. Left eye was normal. There was no past history of varicella in the infant and neither was she vaccinated for varicella. Her mother had developed varicella infection during 7th month

of gestation and was treated with tablet acyclovir five times a day for 7 days with other symptomatic drugs. Systemic examination and developmental milestones of the child were assessed by pediatrician and were normal. Child was irritable and so, was admitted. Treatment with injection acyclovir 75 mg intravenously three times a day for 7 days was initiated. Antibiotics were started to combat secondary bacterial superinfection. Topical mupirocin ointment and acyclovir eye drops were also added. Giemsa stained Tzanck smear showed presence of multinucleated giant cells, an epithelial cell containing numerous nuclei (Fig. 2a). Papanicolaou stained smear from scraping showed presence of acantholytic cells (Fig. 2b). Parents and child were also screened for human immunodeficiency virus (HIV) and both of them along with child came nonreactive for both HIV type I and II. Symptoms subsided remarkably within 1 week of treatment (Fig. 3). Right eye showed hyperemic conjunctiva with no other signs of ocular involvement.

DISCUSSION

Herpes virus is a neurotropic virus³. HZ occurs more commonly in elderly patients but is rare in childhood⁴. It has milder course with less residual damage in children than adults⁵. Varicella-zoster virus is responsible for both varicella and HZ¹. Once a person suffers from varicella infection, the virus remains dormant in dorsal ganglion of spinal nerve root of spinal cord². As immunity decreases, these virus reactivate to produce HZ². If mother suffers from varicella infection in second-half of pregnancy, then there are higher chances

of the child suffering from HZ in 1st year of life⁶. Similar observation was seen in our case. Infantile HZ is due to intrauterine infection of varicella-zoster virus than postnatal⁶. Generally HZ occurs in children with immunodeficiency like malignancy or HIV infection, but it can also occur in immunocompetent individuals⁵. HZ affects eye in 10%-20% cases⁴.

Hutchinson's sign is presence of vesicles on tip/side of nose which indicate involvement of nasociliary nerve of ophthalmic division of trigeminal nerve⁷. If Hutchinson's sign is positive, it means sight-threatening ocular changes can occur⁸. In our case, there was involvement of tip of nose.

In our case, there was history of maternal infection of varicella at the 28th week of gestation. Maternal varicella before 28 weeks of gestation increases chances of congenital varicella syndrome (CVS) in newborn and risk is negligible after 28 weeks of gestation. CVS includes multiple developmental defects like microcephaly, hydrocephaly, aplasia of brain, limb hypoplasia, Horner's syndrome, etc. In our case, mother suffered from varicella at 28 weeks of gestation; hence newborn did not suffer from CVS.

In our case, fetus was exposed to varicella in third trimester in intrauterine life but child developed HZO without developing clinical symptoms of varicella due to the presence of maternal antibody. This is similar to case reported by Van Aelst et al in a 2.5-year-old child⁹.

Varicella vaccine is live attenuated vaccine; so contraindicated in pregnancy and immunocompromised patients, but it can be given prior to conception¹⁰. Two doses are given 1 month apart. In our case, the mother had no history of varicella in past and there are no studies in literature where such cases are to be vaccinated with varicella vaccine before planning for pregnancy.

CONCLUSION

There are only few published reports on HZ ophthalmicus in immunocompetent children in Indian

literature. We are reporting this case as rare pediatric case of HZO in an immunocompetent infant. This case report demonstrates that HZ ophthalmicus can occur in an immunocompetent child with a history of varicella infection to mother during late gestational months. Early diagnosis and treatment decrease fatal complications. Also, preconception vaccination of females not exposed to varicella-zoster virus in past is a matter of concern.

REFERENCES

1. Weller TH. Serial propagation in vitro of agents producing inclusion bodies derived from varicella and herpes zoster. *Proc Soc Exp Biol Med*. 1953;83(2):340-6.
2. Hope-Simpson RE. The nature of herpes zoster: a long-term study and a new hypothesis. *Proc R Soc Med*. 1965;58(1):9-20.
3. Savage MO, Moosa A, Gordon RR. Maternal varicella infection as a cause of fetal malformations. *Lancet*. 1973;1(7799):352-4.
4. Ragozzino MW, Melton LJ 3rd, Kurland LT, Chu CP, Perry HO. Population-based study of herpes zoster and its sequelae. *Medicine (Baltimore)*. 1982;61(5):310-6.
5. Liesegang TJ. Herpes zoster ophthalmicus natural history, risk factors, clinical presentation, and morbidity. *Ophthalmology*. 2008;115(2 Suppl):S3-12.
6. Enders G, Miller E, Craddock-Watson J, Bolley I, Ridehalgh M. Consequences of varicella and herpes zoster in pregnancy: prospective study of 1739 cases. *Lancet*. 1994;343(8912):1548-51.
7. Frary J, Petersen PT, Pareek M. Hutchinson's sign of ophthalmic zoster. *Clin Case Rep*. 2019;8(1):219-20.
8. Zaal MJ, Völker-Dieben HJ, D'Amaro J. Prognostic value of Hutchinson's sign in acute herpes zoster ophthalmicus. *Graefes Arch Clin Exp Ophthalmol*. 2003;241(3):187-91.
9. Van Aelst S, Winters L, Janssen K, Laffut W, Thibaut K. A healthy 2.5-year-old boy with herpes zoster ophthalmicus as primary presentation. *J Pediatric Infect Dis Soc*. 2015;4(4):e160-2.
10. Centers for Disease Control and Prevention. Morbidity and Mortality Weekly Report Prevention of Varicella Recommendations of the Advisory Committee on Immunization Practices (ACIP). *Morb Mortal Wkly Rep Recomm*. 2007;56(4):7.

