

Unveiling the Eschar: A Mite's Mark in Scrub Typhus

BV NAGABHUSHANA RAO*, T SRAVANTHI*, R SUNEETHA*, MS MOUNICA*

ABSTRACT

Scrub typhus is an acute febrile illness caused by *Orientia tsutsugamushi*, a Gram-negative intracellular organism transmitted by *Leptotrombidium* mites, with wild rats serving as natural reservoirs. The disease is more common in the Tsutsugamushi Triangle, often afflicting travelers and creating diagnostic challenges in clinical practice. We present the case of a diabetic patient who acquired the infection while visiting an agricultural farm. Our discussion covers clinical manifestations, diagnostic markers and treatment modalities, emphasizing the significance of early recognition and the benefits of prompt treatment. The importance of searching for an eschar, a key physical sign, is underscored and potential serious outcomes are discussed. Recent advances and preventive measures are also highlighted. This synthesis of research and clinical insights aims to enhance global awareness, prompt diagnosis and effective management of scrub typhus.

Keywords: Eschar, fever-mite, tsutsugamushi, scrub typhus, international travelers

Scrub typhus is an acute febrile illness caused by infection with *Orientia tsutsugamushi*, an intracellular obligate Gram-negative organism. It is transmitted to humans by the bite of the infected chigger, the mite of *Leptotrombidium*. Wild rats serve as the natural reservoir, with humans as accidental victims. Chiggers, measuring 0.2 mm, are challenging to visualize with the naked eye. They typically inhabit scrubs, the transitional area between woods and clearings, hence the term "Scrub Typhus". In tropical regions, infections can occur year-round, while in the Far East, infections peak from July to September.¹

The geographical distribution of this disease forms a triangular area extending from northern Japan in the east to eastern Russia in the north, Afghanistan and Pakistan in the west and northern Australia in the south, known as the Tsutsugamushi Triangle. Approximately half of the human population resides in this area. Scrub typhus is often acquired during occupational or agricultural exposure.² An estimated 1 million cases occur annually and around 1 billion people in

the endemic areas are possibly being infected at some point. In India, although clear statistics are lacking, a literature search from the past 10 years reported 18,781 confirmed cases.³

The incubation period ranges from 6 to 20 days, with an average of 10 days. Patients commonly present with high fever, cough, malaise, anorexia, ocular pain, lymphadenopathy and splenomegaly. Severe cases may involve pneumonitis, encephalitis, myocarditis, hepatitis, renal failure and, rarely, complications such as acute respiratory distress syndrome, circulatory failure and disseminated intravascular coagulation. A diagnostic sign is the presence of an eschar at the chigger bite site, with a maculopapular rash potentially developing on the 5th to 8th day. Mortality rates vary from 1% to 60%, depending on the strain and geographical area, with poor prognostic factors including age over 60, high initial leukocyte count, elevated C-reactive protein (CRP), abnormal liver function tests and the absence of an eschar.⁴

Doxycycline is the preferred treatment, and alternatives include azithromycin, rifampin and chloramphenicol. Chemoprophylaxis with weekly doxycycline starting a week before and continuing for 6 weeks after exposure is advisable. Wearing appropriate clothing or using repellent to prevent mite bites and employing a cloth barrier while in the scrubs are recommended preventive measures.⁵

*Consultant General Physician
Dept. of Medicine, Queens NRI Hospital, Visakhapatnam, Andhra Pradesh, India
Address for correspondence
Dr BV Nagabhushana Rao
Consultant General Physician
Dept. of Medicine, Queens NRI Hospital, Visakhapatnam - 530013, Andhra Pradesh, India
E-mail: bhavanavnrao@gmail.com

CASE SUMMARY

A 54-year-old male was admitted to the hospital on 24th July, 2023 with an 8-day history of fever with chills. He had an ulcer with surrounding erythema on the left thigh (Fig. 1), and vaguely recalled being bitten by an insect in the same area a week before the ulcer developed. This incident occurred during an outdoor party at a friend's farmhouse in a suburban area. The patient developed an erythematous maculopapular rash on the day of admission (Fig. 2). He had a 20-year

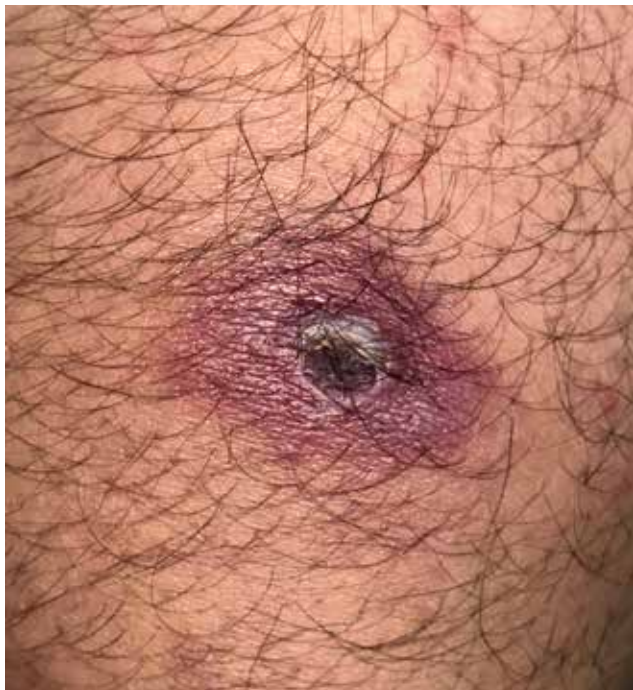

Figure 1. Eschar, consisting of a central tough black scab surrounded by dull red areola. It is neither pruritic nor painful.

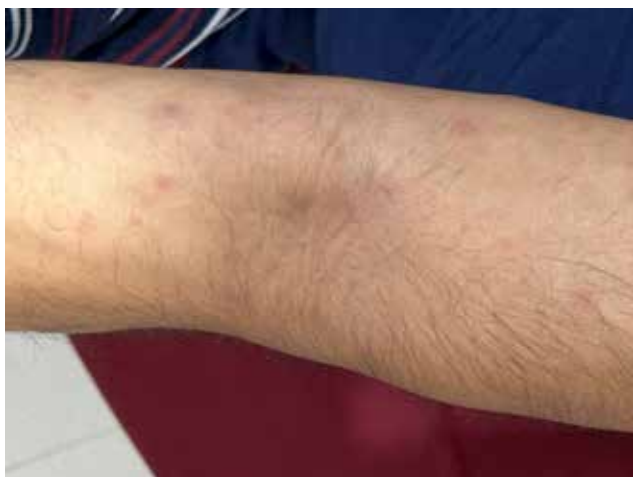

Figure 2. Maculopapular rash usually appearing first on the trunk and spreading (centripetal) to limbs between 5th to 8th day illness

history of diabetes treated with a combination of insulin aspart and insulin aspart protamine and had taken an antibiotic (amoxicillin clavulanate) initially but discontinued it due to gastrointestinal side effects. He had taken cefuroxime for 3 days before admission. The patient was febrile with a temperature of 103°F (Fig. 3), normal blood pressure and a pulse rate of 101/min. Physical examination revealed clear lungs, tachycardia, mild abdominal distension with no tenderness and restlessness. Laboratory investigations are detailed in Table 1.

Based on clinical presentation, the presence of an eschar and a positive rapid immunochromatographic test for IgM against *O. tsutsugamushi*, a diagnosis of scrub typhus was established. The patient was treated with doxycycline and azithromycin and showed a favorable response by the 3rd day, with the fever resolving and ulcer healing by the 5th day. The patient was discharged on a regimen of doxycycline and azithromycin, and after a 10-day follow-up, the patient was healthy with complete healing of the ulcer.⁶

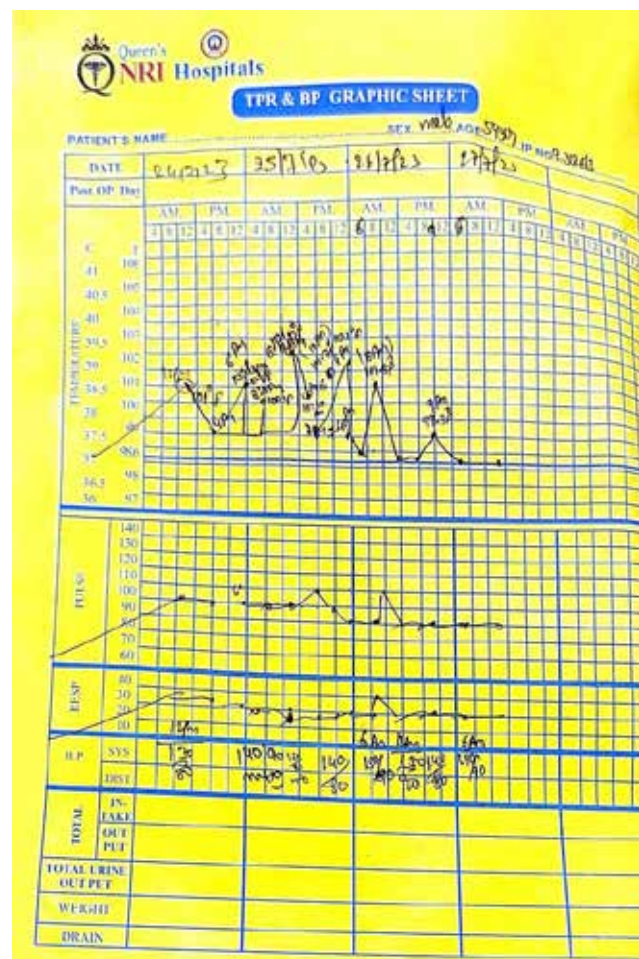


Figure 3. Patient's temperature chart showing fever spikes.

Table 1. Laboratory Investigations

TWBC: 7,000/ μ L
 Hb%: 14.0 g
CRP: 23.71 mg
 Peripheral smear: Normal
 LDH: 364 Unit/L
 Urine microscopy: 6-8 pus cells
 Dengue serology: Negative
 QBC malaria: Negative
 IgM typhoid: Negative
 HBsAg: Negative
 HCV: Negative
 HIV: Negative
IgM scrub typhus: Positive
 Ultrasound abdomen: Cholelithiasis
 Chest X-ray: Normal
 ECG: Normal
 Urine culture and sensitivity: No growth
 Blood culture and sensitivity: No growth

TWBC = Total white blood cells; Hb = Hemoglobin; CRP = C-reactive protein; LDH = Lactate dehydrogenase; QBC = Quantitative buffy coat; IgM = Immunoglobulin M; HBsAg = Hepatitis B surface antigen; HCV = Hepatitis C virus; HIV = Human immunodeficiency virus; ECG: Electrocardiogram.

DISCUSSION

The patient likely contracted scrub typhus while visiting an agricultural farm, commonly associated with activities in scrubs or agriculture. The presence of a typical eschar at the insect bite site supported the diagnosis, although its absence does not exclude the disease. The patient exhibited high-grade spiky fever, a common symptom in scrub typhus cases. The maculopapular rash on the 8th day aligned with the typical presentation, and although the patient had a normal leukocyte count, literature suggests initial lymphopenia followed by lymphocytosis is common. Poor prognostic indicators, such as increased CRP, were present in this case. A positive rapid test for IgM is a common method for diagnosing scrub typhus in developing countries. Pulmonary involvement, often seen as patchy pneumonia, did not manifest radiologically in this patient.⁷

Differential diagnoses include leptospirosis, dengue, malaria, typhoid, anthrax, rickettsial pox, tularemia and viral fevers with thrombocytopenia. Diagnosis may be challenging in the absence of a typical eschar.

Interestingly, in human immunodeficiency virus (HIV)-positive patients infected with certain strains of scrub typhus, a dramatic decrease in viral load has been

observed, sparking research interest.⁸ Treatment choices involve doxycycline and azithromycin, either individually or in combination, depending on the clinical scenario. Our patient responded favorably to treatment, emphasizing the importance of timely intervention. If a patient does not respond, re-evaluation of the diagnosis or consideration of drug resistance is crucial.⁹

CONCLUSION

Scrub typhus can be fatal if not diagnosed early and treated appropriately. Clinical presentations and laboratory parameters may mimic other febrile illnesses, necessitating a thorough search for an eschar as a vital diagnostic clue. Scrub typhus should be considered in the differential diagnosis, particularly when treating febrile illnesses in travelers from endemic areas.

Acknowledgment

We sincerely thank Dr Chalasani Vijayalakshmi, Chairperson of the Queen's NRI Hospital, Visakhapatnam, for allowing us to publish the case.

Declarations

Funding: None.

Conflict of interest: None declared.

Ethical approval: Not required.

REFERENCES

- Ogawa M, Hagiwara T, Kishimoto T, Shiga S, Yoshida Y, Furuya Y, et al. Scrub typhus in Japan: epidemiology and clinical features of cases reported in 1998. *Am J Trop Med Hyg.* 2002;67(2):162-5.
- Sharma PK, Ramakrishnan R, Hutin YJ, Barui AK, Manickam P, Kakkar M, et al. Scrub typhus in Darjeeling, India: opportunities for simple, practical prevention measures. *Trans R Soc Trop Med Hyg.* 2009;103(11):1153-8.
- Devasagayam E, Dayanand D, Kundu D, Kamath MS, Kirubakaran R, Varghese GM. The burden of scrub typhus in India: a systematic review. *PLoS Negl Trop Dis.* 2021;15(7):e0009619.
- Kim DM, Kim SW, Choi SH, Yun NR. Clinical and laboratory findings associated with severe scrub typhus. *BMC Infect Dis.* 2010;10:108.
- Olson JG, Bourgeois AL, Fang RC, Coolbaugh JC, Dennis DT. Prevention of scrub typhus. Prophylactic administration of doxycycline in a randomized double blind trial. *Am J Trop Med Hyg.* 1980;29(5):989-97.
- Rodkvamtook W, Prasartvit A, Jatisatiern C, Jatisatiern A, Gaywee J, Eamsobhana P. Efficacy of plant essential oils for the repellents against chiggers (*Leptotrombidium imphalum*) vector of scrub typhus. *J Med Assoc Thai.* 2012;95 Suppl 5: S103-6.

7. Chen HC, Chang HC, Chang YC, Liu SF, Su MC, Huang KT, et al. Chest radiographic presentation in patients with scrub typhus. *Trans R Soc Trop Med Hyg.* 2012;106(1):48-53.
8. Watt G, Kantipong P, de Souza M, Chanbancherd P, Jongsakul K, Ruangweerayud R, et al. HIV-1 suppression during acute scrub-typhus infection. *Lancet.* 2000;356(9228):475-9.
9. Varghese GM, Dayanand D, Gunasekaran K, Kundu D, Wyawahare M, Sharma N, et al; INTREST Trial Investigators. Intravenous doxycycline, azithromycin, or both for severe scrub typhus. *N Engl J Med.* 2023;388(9):792-803.



Characteristics of Hyperosmolar Hyperglycemic State in Diabetes Patients

Patients with type 1 diabetes are more likely to experience hyperosmolar hyperglycemic state (HHS) compared those with type 2 diabetes, as per a new study reported in *Diabetes Care*,¹ which also states that HHS is considered a spectrum of hyperglycemic crises and can be further categorized into two subgroups: pure HHS and HHS-DKA (diabetic ketoacidosis).

Researchers from the Copenhagen University Hospital and the University of Copenhagen sought to evaluate the incidence of HHS and also examine the clinical and biomarker profiles of patients with HHS, including those with acidosis and acute kidney injury (AKI). For this they conducted a descriptive cohort study using Danish registry data from 2016 to 2018. Patients having a glucose level of ≥ 33 mmol/L and an osmolarity (calculated as $2 \times \text{sodium} + \text{glucose}$) of ≥ 320 mmol/L were included in the study. A total of 24,196 had type 1 diabetes, while the number of adults diagnosed with type 2 diabetes was 2,51,357.

A total of 634 adult patients with an average age of 69 years and who met the criteria for HHS among a population of 4.80 million individuals were included in the study. The incidence rate of HHS in patients with known type 1 diabetes was 16.5 per 10,000 person-years and in patients with known type 2 diabetes, the incidence rate was 3.9 per 10,000 person-years. Interestingly, 32% of the patients diagnosed with HHS had not previously been diagnosed with diabetes.

The researchers further categorized the total HHS patients into two groups: 394 had pure HHS, while 240 had combined HHS and DKA. Patients in the pure HHS group were older than the HHS-DKA group. Sixty-five percent of patients in the pure HHS group had AKI at the time of hospitalization. Of these, just 6.2% had a chronic renal disease. "Among the patients with pure HHS who did not receive a DKA diagnosis during hospitalization, 39% still had an acidosis". The in-hospital mortality rate for patients with pure HHS was found to be 17% compared with 9% among those with HHS-DKA

HHS is a rare but acute condition and carries a high mortality rate. This study illustrates the incidence and characteristics of HHS in patients with diabetes. It is important to characterize HHS to help physicians to promptly recognize and diagnose this acute illness and take appropriate measures so that effective and rapid treatment can be initiated upon arrival at the hospital. Here, it also becomes important to note that it can sometimes be the initial indication of underlying diabetes, as was the case in this study, where HHS was actually the first presentation of their diabetes diagnosis.

Reference

1. Rosager EV, et al. Incidence and characteristics of the hyperosmolar hyperglycemic state: a Danish cohort study. *Diabetes Care.* 2024;47(2):272-9.